



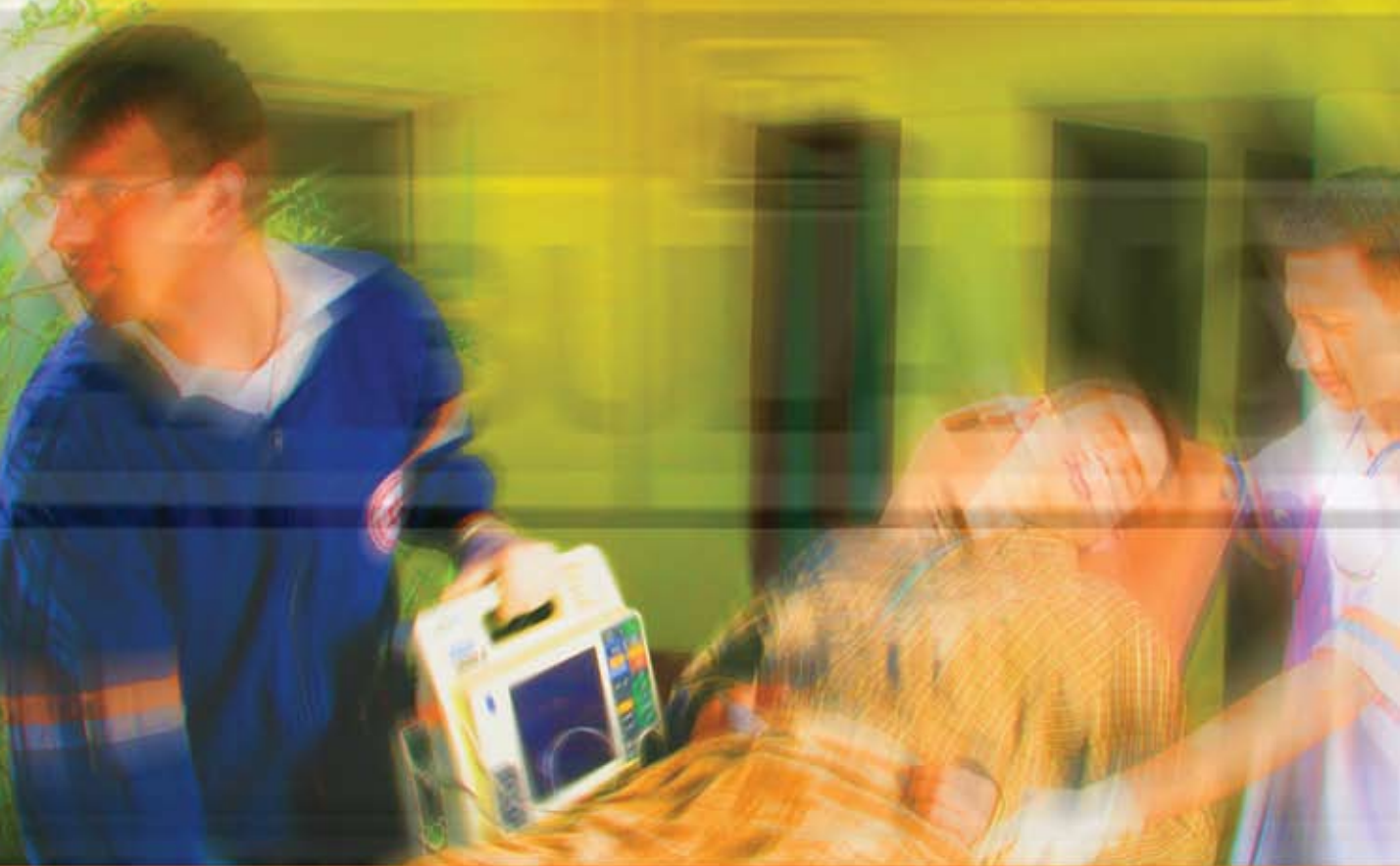Measuring LIFE & BREATH

The benefits of capnography in EMS



Oridion® JEMS

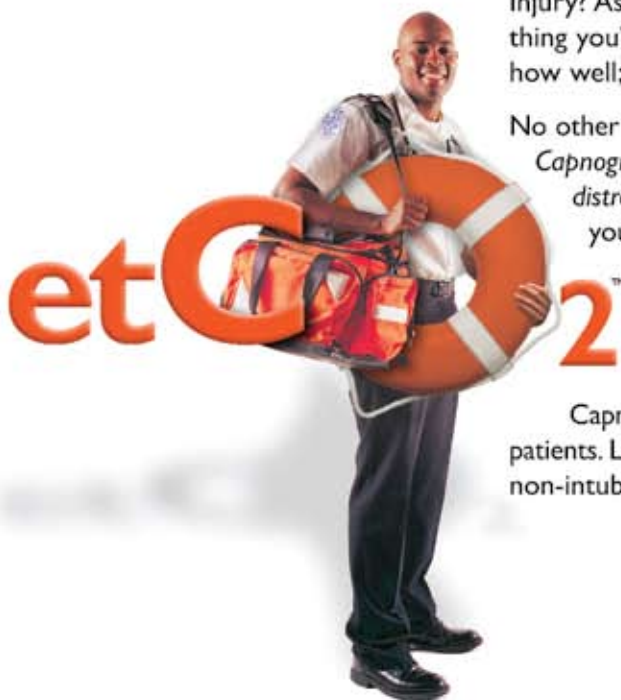
An exclusive supplement to JEMS sponsored by Oridion.



**You need to know if your patient is breathing.
You need capnography.**

7:41 a.m. The call – a man found unconscious. Is it a heart attack? Injury? Asthma? Whatever his condition, you're ready. Because the first thing you'll need to know when you get there is if he's breathing, and how well; you've got that covered with capnography.

No other vital sign can tell you whether your patient is ventilating properly. *Capnography provides the earliest, most accurate indication of respiratory distress and gives you a continuous, breath-by-breath assessment of your patient's ventilatory status.*



2™ With all the uncertainties each call brings, there is one certainty you can count on: capnography. Simple. Fast. Accurate. *Certainty in an uncertain world.*

Capnography has long been the standard for monitoring intubated patients. Learn why capnography is becoming the new standard for non-intubated ventilation monitoring at www.oridion.com/ems.



Oridion®

TABLE OF CONTENTS



Vice President/Publisher
Jeff Berend

Advertising Director
Judi Leidiger

Editorial Director
A.J. Heightman, MPA, EMT-P

Art Director
Leah Bergman

Managing Editor
Lauren Hardcastle

Cover Photo
Oridion

4 | CAPNOGRAPHY BASICS

An invaluable tool for providers & their patients

Pat Brandt, RN

10 | POSITIVE JUSTIFICATION

A cost-benefit analysis of capnography use can prove value to patients & your budget

Pat Brandt, RN

14 | A FORM OF TRIAGE

Capnography use for the conscious & non-intubated patient

Bob Page, AAS, NREMT-P, CCEMT-P, NCEE

18 | GOTHCA!

Challenging waveforms that could fool an expert

Pat Brandt, RN

INTRODUCTION

THE ULTIMATE TREND SETTER



By A.J. Heightman, MPA, EMT-P

The 2010 AHA Guidelines for CPR and ECC have a major new Class I recommendation for use of quantitative waveform capnography for confirmation and monitoring of endotracheal (ET) tube placement. Real-time monitoring and optimization of CPR quality using physiologic parameters, such as partial pressure of end-tidal carbon dioxide (PetCO₂), are encouraged. The guidelines also recommend the use of capnography PetCO₂ values to monitor CPR quality, detect return of spontaneous circulation and guide vasopressor therapy during cardiac arrest (Class IIb).

In EMS circles, capnometry used to just be a tool for determining whether an ET tube was properly placed. It soon became the gold standard for this function. However, medical directors, educators and field crews in most EMS systems soon realized that capnography was a multi-purpose assessment tool.

Capnography is the only single-monitoring modality available to EMS crews that provides a visual reference to a patient's ABCs in less than 15 seconds, with a normal waveform instantly telling us our patient's airway is patent, they're breathing, and they're adequately perfusing.

Capnography also provides the only direct, non-invasive measure of ventilatory status available to EMS crews and offers

the earliest indication of hypoventilation, respiratory depression and respiratory failure.

Most importantly, changes in the capnography waveform provide the earliest indication of apnea, upper airway obstruction and laryngospasm. A glance at the waveform by a trained provider allows them to instantly see a patient's response to airway alignment maneuvers and further distinguish upper airway obstruction from laryngospasm. Providers can also easily recognize the curved waveform of obstructive lung disease, which indicates bronchospasm.

Capnography can also be used effectively to detect, assess and triage victims of chemical terrorism. It's helpful as an assessment and triage tool because chemical agents are primarily absorbed through the skin and respiratory tract and have their greatest effect on the central nervous and respiratory systems.

Because EtCO₂ waveforms and trends alert crews to worsening conditions and allow them to intervene much earlier to correct or reverse a critical condition, capnography is one of the most important EMS assessment tools that can be carried in a critical care toolkit for conscious and unconscious patients.

Pass this special supplement to December *JEMS* along to your personnel and ensure your crews are fully utilizing all the important capabilities offered by capnography. •

CAPNOGRAPHY BASICS

An invaluable tool for providers & their patients

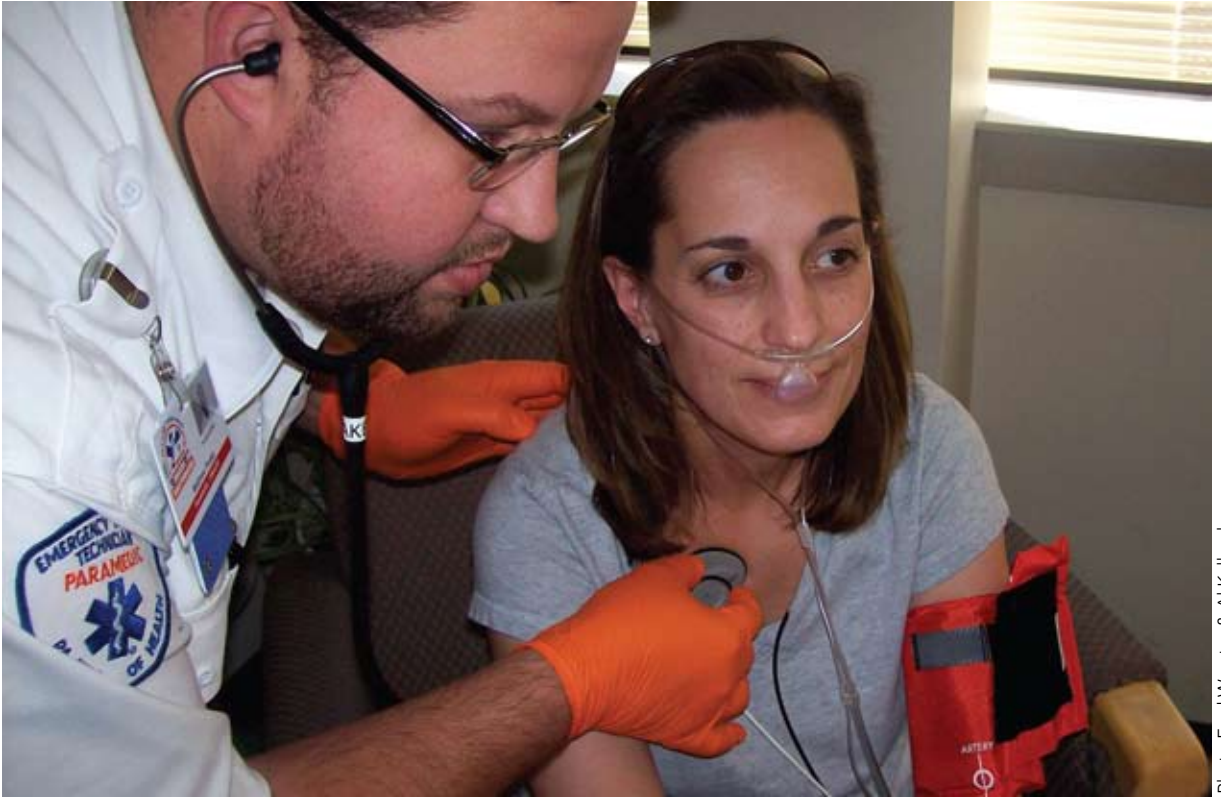

Photo: Fred Wurster & Al Kalbach



By Pat Brandt, RN

The goal of this supplement is to review key aspects of capnography, its powerful assessment capabilities on intubated and conscious patients, and its importance as a prehospital triage and treatment guiding tool.

Capnography provides valuable and rapid assessment information that greatly assists EMS providers and enables them to develop, monitor and modify patient care plans. This valuable assessment tool supplies immediate breath-to-breath information about the patient's respiratory status: Are they being adequately ventilated? Are they breathing too quickly or slowly? Are they experiencing bronchospasm?

Capnography also provides you with key information about the patient's circulatory status, such as whether they have adequate cardiac output and

are perfusing well. In addition, it gives you key information about the patient's metabolic status, such as whether they have normal metabolic activity or if it increased or decreased.

This information, when combined with the patient's history and your physical assessment, can provide you with an accurate working diagnosis of the emergency condition. Once that clinical observation is made, you can initiate the appropriate treatment for that condition. Then you can continue to observe the capnography trend and use it to assist you in determining the effectiveness of the treatment and guide you in continuing or adjusting your treatment as required.

These outstanding assessment capabilities exhibit why capnography is required in multiple states and on every ALS unit in Europe.

Capnography is now required in most EMS systems to ensure successful patient endotracheal intubation.

Definition

Capnography offers a quantitative numerical reading and graphic waveform that measures, illustrates and documents your patient's exhaled carbon dioxide (CO₂). All living human beings produce CO₂ as a byproduct of metabolism. The carbon dioxide, once produced, is diffused into the blood and transported to the lungs via the circulatory system. It's then released by the alveoli and eliminated from the body during exhalation.

Therefore, capnography enables you to evaluate the current status of the patient's ventilatory, circulatory and metabolic systems by measuring the exhaled CO₂ and graphically depicting its path of exhalation.

Capnography Use

Capnography not only provides you with a rapid and reliable assessment of the patient's ventilatory, circulatory and metabolic function, it also—and more importantly—represents real-time information regarding CO₂ exhalation and respiratory rates.

In the articles that follow, several actual cases will illustrate the effectiveness of capnography as an assessment and monitoring tool in the field.

The measurement of CO₂ content in *each* exhalation reflects the CO₂ produced by metabolism, transported by the circulatory system and exhaled by the respiratory system at the time of that particular breath. This allows you to make rapid adjustments in your treatment based on current information.

Application

It's important you understand capnography's numerical readings and graphic waveforms to use it effectively. The numeric readings are derived from a point in the respiratory cycle known as the end-tidal CO₂ (EtCO₂). This is the point at the end of exhalation when the CO₂ reaches its highest concentration. This concentration is generally in the range of 35–45 mmHg.

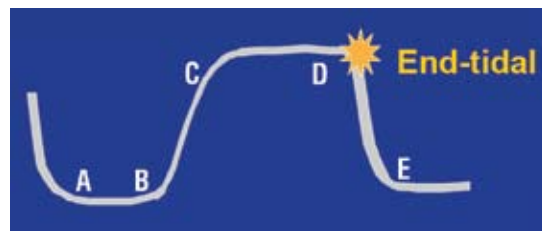
The reading closely correlates to the CO₂ levels

Capnography represents real-time information regarding CO₂ exhalation and respiratory rates.

measured with arterial blood gases in patients with normal lung function and also in patients with abnormal lung function due to conditions other than a ventilation-perfusion mismatch.

In patients with a ventilation-perfusion mismatch, the gradient between the ventilation and the perfusion will widen based on the severity of the mismatch. In those cases, the EtCO₂ should be used to trend the ventilatory status. An elevated EtCO₂ level is typically an indication of hypoventilation or increased metabolic activity. A low exhaled CO₂ level

FIGURE 1



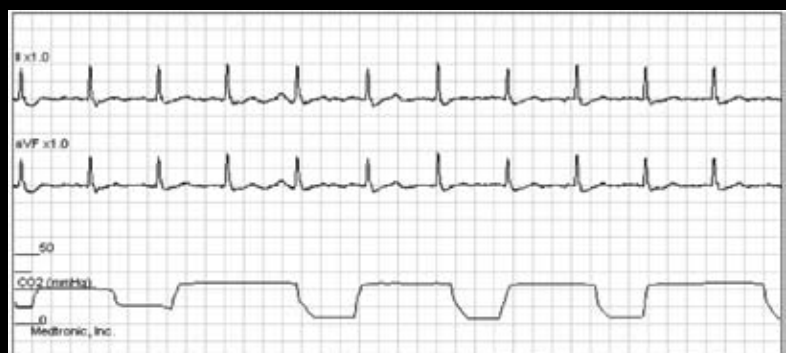may be an indication of hyperventilation, decreased cardiac output or poor pulmonary perfusion, which can occur in shock.

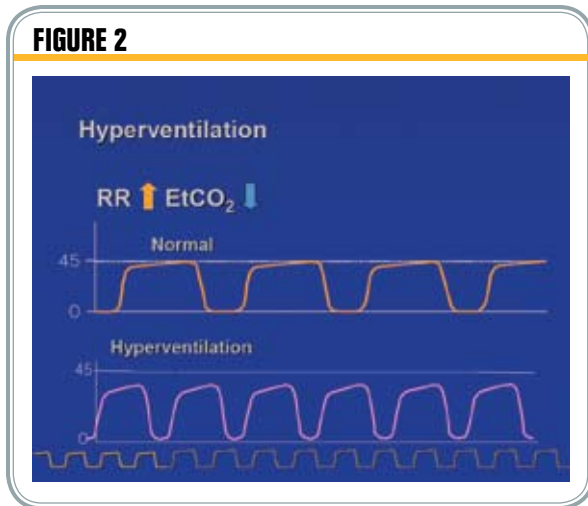
The capnography waveform can be compared to an ECG because the “normal” waveform has certain rules. Each waveform represents the various phases of inhalation and exhalation and is divided into four phases, (see Figure 1 above).

Phase I (A–B) occurs at the beginning of exhalation when no CO₂ is present in the upper airway, trachea, posterior pharynx, mouth and nose. No gas exchange occurs in these areas, so this “dead space”

Hyperventilation Example

This is a hyperventilation waveform. Note the high RR and low EtCO₂.





is represented as the flat baseline of the waveform.

Phase II (B–C) is the ascending phase. During this phase, CO₂ from the alveoli begins to reach the upper airway and mix with the dead space air, causing a rapid rise in the amount of CO₂ detected.

Phase III (C–D), the alveolar plateau, reflects a uniform concentration of CO₂ from the alveoli to the mouth and nose. It culminates with the EtCO₂ (D) at the end of the exhalation, which contains the highest level of CO₂.

Phase IV (D–E) is the descending phase. It's when inhalation begins. As oxygen fills the airway, the CO₂ level rapidly returns to 0, or back to the baseline. This box-like appearing waveform is the classic, normal capnography waveform.

There are three basic abnormal capnography waveforms:

1. Hypoventilation waveform;
2. Hyperventilation waveform; and
3. Bronchospastic waveform.

The hypoventilation waveform, related to a decreased respiratory rate, will have fewer waveforms, with each presenting increased height due

to the presence of more CO₂ per breath, (see Figure 3, p. 8). There are, however, other reasons for an increased EtCO₂ and increased waveform height. These include a decreased tidal volume with or without a decreased respiratory rate, an increased metabolic rate and an increased body temperature.

The hyperventilation waveform, related to an increased respiratory rate, will have a higher number of waveforms with a decreased height of the waveforms due to the presence of less CO₂ per breath, (see Figure 2). As mentioned earlier, other reasons for a decreased EtCO₂ and decreased waveform height include increased tidal volume, a decreased metabolic rate, a decrease in circulation and hypothermia.

The bronchospastic capnography waveform is recognized by a shark-fin shape instead of the normal box-like waveform, (see Figure 4, p. 9). This is because bronchospasm causes a slower and more erratic emptying of CO₂ from the alveoli, which results in a slower rise in the expiratory upstroke.

Other, less common waveform abnormalities do occur, so read "Gotcha!" on p.18 of this supplement for more about those abnormalities.

Proper Usage

By now it should be evident that capnography is indicated in almost every prehospital emergency. What other tool can provide you with a real-time window into your patient's ventilation, metabolism and circulation? Capnography helps you take remedial intervention in hypoxic states before irreversible brain damage occurs, and it's proven to be a better indicator of hypoxia than clinical observation alone.¹

Initially, capnography was primarily used by anesthesiologists in the operating room to monitor the respiratory status of intubated or mechanically ventilated patients. Eventually, it was adopted for

Bronchospasm Example

This is a bronchospasm waveform example. Note the shark-fin appearance.

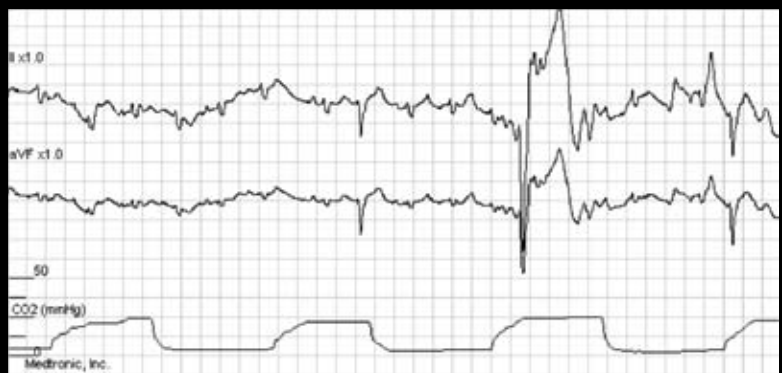

Figure Pat Brandt



Photo Oridion

this same purpose by prehospital EMS systems.

Using capnography to ensure successful intubation has become the gold standard and is now required in most EMS systems. The detection of CO₂ on expiration is a completely objective confirmation of tracheal intubation.²

Because capnography indirectly correlates with cardiac output under conditions of constant ventilation, it has many extremely beneficial uses for cardiac arrest patients (as referenced in the 2010 AHA CPR and ECC Guidelines):

1. Determine the effectiveness of cardiac compressions. For example, during CPR, providers will be able to visually see a gradually decreasing waveform height as the rescuer providing compressions tires. This allows for an early warning to change compressions;
2. Recognize the return of spontaneous circulation (ROSC) via digital and graphic waveform readings presented; and
3. Assist prehospital crews to make decisions about terminating resuscitation.³

Capnography can also be effectively used with the Combitube, the laryngeal mask airway or any supraglottic airway device. It can also be used with bag-valve-mask ventilation.

In addition to being an essential tool in intubated patients, capnography is quickly becoming a valued assessment method in the non-intubated patient. The noninvasive monitoring capabilities of

capnography have contributed greatly to the care and survival of acutely ill patients of all age groups and conditions.

Respiratory Conditions

Capnography can be effectively used during the assessment and treatment of asthma and chronic obstructive pulmonary disease (COPD) patients to detect the presence and severity of bronchospasm. It can also guide treatment decisions when the shark fin denoting bronchospasm doesn't improve or even worsens, (see example, p. 6).

This capnography use can be particularly helpful in determining when, or if, to move to the next level of treatment, including intubation or continuous positive airway pressure (CPAP). The capnography level of patients receiving CPAP treatment can be continually monitored through use of a special nasal/oral cannula.

Patients who are sedated or receiving pain management can be monitored for hypoventilation, and capnography can assist in decisions regarding continued administration of sedatives or pain control.⁴

In these cases, hypoventilation will be demonstrated by gradually increasing EtCO₂ and waveform height, allowing the provider to terminate the administration of the central nervous system, depressant medications and assist ventilations or intubate when indicated, (see example p. 8).

Decisions regarding the need for intubation or

▲
Always ensure your EtCO₂ sampling line is properly inserted and secured in the monitor. Check this connection if your reading doesn't seem to correspond with your patient's condition.

Hypoventilation Example

This is a hypoventilation waveform. Note the low RR and high EtCO₂ with a 0–100 scale.

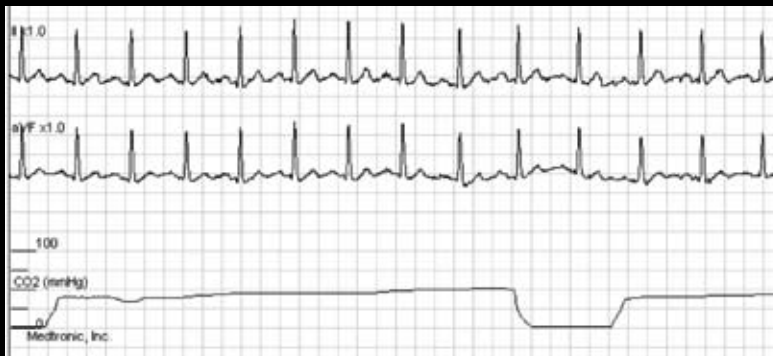


Figure Pat Brandt

assisted ventilation for the overdose patient can also be guided by capnography, particularly as respiratory drive decreases.

Patients who are hyperventilating and exhibiting anxiety can be particularly difficult to diagnose. Determining whether you're dealing with a psychological event or severe pathophysiology can be challenging in the presence of disease processes that have few clinical findings, such as the patient with a pulmonary embolus.

A low exhaled CO₂ level may be an indication of hyperventilation, decreased cardiac output or poor pulmonary perfusion, which can occur in shock.

Capnography can assist you in determining a clinical pathway for these patients, because hyperventilation with normal or high EtCO₂ levels is much more likely to reflect pathology, whereas hyperventilation with low EtCO₂ levels is more likely to reflect anxiety, (see example p. 5).

Capnography waveforms can also be used as a biofeedback technique when coaching anxious patients to decrease their respiratory rate. Have the patient view the rapid waveforms on the screen and attempt to slow them. This can be quite effective.

Metabolic Conditions

Capnography can also be used effectively in

patients with diabetes mellitus, especially to evaluate the patient for diabetic ketoacidosis.

A 2002 study demonstrated that in diabetic children presenting to the emergency department with an EtCO₂ of less than 29 mmHg, 95% were in ketoacidosis, whereas if the EtCO₂ was greater than 36 mmHg, no ketoacidosis was found.⁵

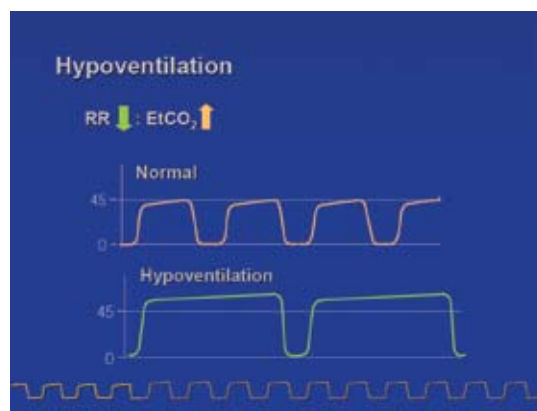
Capnography works effectively in determining the treatment for sympathomimetic overdoses. This includes the administration of benzodiazepines, which can be guided by the extent of the increase in metabolic rate, reflected in the amount of increase in EtCO₂.

The severity of hyperthermia and hypothermia can be assessed with capnography, and it can help you adjust your treatment of a patient. It can also determine the severity of metabolic acidosis in gastroenteritis, especially in children.⁵

Circulatory Conditions

Capnography provides an indirect, real-time window to your patient's circulatory status and is an excellent way to trend for all types of potential

FIGURE 3



shock states.

Because it reflects circulatory status, and indirectly reflects cardiac output, EtCO₂ may decrease before changes in systolic blood pressure occur. For this reason, capnography should be carefully monitored in patients with acute myocardial infarction, (see Figure 3, p. 8). Capnography can be particularly helpful in assessing the circulatory status of the patient experiencing a right-ventricular infarction or an inferior-wall myocardial infarction with right-ventricular involvement, because these patients often require large amounts of IV fluids to maintain adequate perfusion.

Patients in congestive heart failure (CHF) can present challenges regarding circulatory status and also treatment decisions regarding shortness of breath. Although the mainstay of treatment for difficulty breathing in many EMS systems continues to revolve around the administration of bronchodilators, patients experiencing CHF without the presence of bronchospasm have no need for this intervention. Therefore, capnography can prevent the unnecessary use of bronchodilators that may increase heart rate and blood pressure. On the other hand, if bronchospasm is noted on capnography and the patient has co-existent CHF and COPD, bronchodilators can be used appropriately.

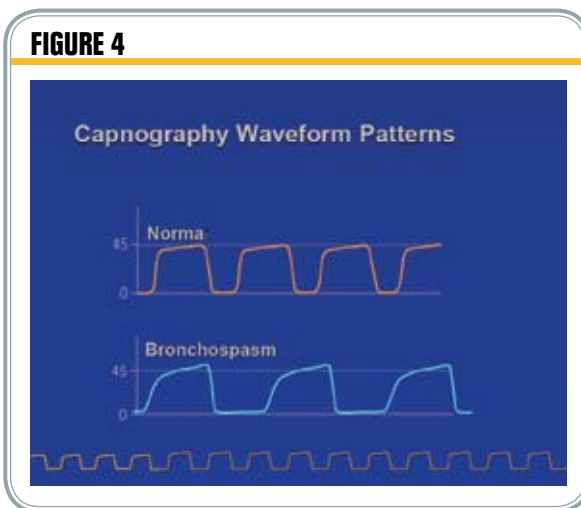
Future Uses

Capnography has been proven to be an invaluable assessment tool that can detect serious patient conditions and guide prehospital and hospital treatment. So what's next?

Ongoing research continues to suggest evidence-based uses for capnography in the prehospital setting. Recent studies have demonstrated the effectiveness of capnography as a primary assessment tool for the detection of pulmonary emboli, sepsis, thyrotoxicosis, malignant hyperthermia, respiratory status of the seizure patient and triage of patients in a bioterrorism incident. And a 2010 study in Australia has suggested the use of capnography to monitor patients for hypercapnia and hypoventilation in the intubated major trauma patient.⁶ The practical uses of capnography in emergency settings are almost limitless, with new uses continually evolving. •

Pat Brandt, RN, has worked in EMS for more than 25 years as an EMS transport nurse, an emergency department nurse, a paramedic educator and an EMS quality manager. She recently retired as the EMS quality manager and paramedic instructor for Orange County (Fla.) Fire Rescue Department. She also

FIGURE 4



served on the state committee in Florida that developed and supported the legislative rules requiring the use of continuous waveform capnography by Florida EMS agencies. Contact her at brandtp@bledsoe.net.

Disclosure: The author has completed contract work for Medtronic/Physio Control Corporation, a manufacturer that utilized Oridion capnography technology in their cardiac monitors.

References

1. Coté CJ, Rolf N, Liu LM, et al. A single-blind study of combined pulse oximetry and capnography in children. *Anesthesiology*. 1991;74:980–987.
2. Silvestri S, Ralls GA, Krauss B, et al. The effectiveness of out-of-hospital use of continuous end-tidal carbon dioxide monitoring on the rate of unrecognized misplaced intubation within a regional emergency medical services system. *Ann Emerg Med*. 2005;45:497–503.
3. Levine RL, Wayne MA, Miller CC. End-tidal carbon dioxide and outcome of out-of-hospital cardiac arrest. *N Engl J Med*. 1997;337:301–306.
4. Krauss B, Hess D. Capnography for procedural sedation and analgesia in the emergency department. *Ann Emerg Med*. 2007;50:172–181.
5. Fearon DM, Steele DW. End-tidal carbon dioxide predicts the presence and severity of acidosis in children with diabetes. *Acad Emerg Med*. 2002;9:1373–1378.
6. Hiller J, Silvers A, McIlroy DR, et al. A retrospective observational study examining the admission arterial to end-tidal carbon dioxide gradient in intubated major trauma patients. *Anaesth Intensive Care*. 2010;38:302–306.

POSITIVE JUSTIFICATION

A cost-benefit analysis of capnography use can prove value to patients & your budget

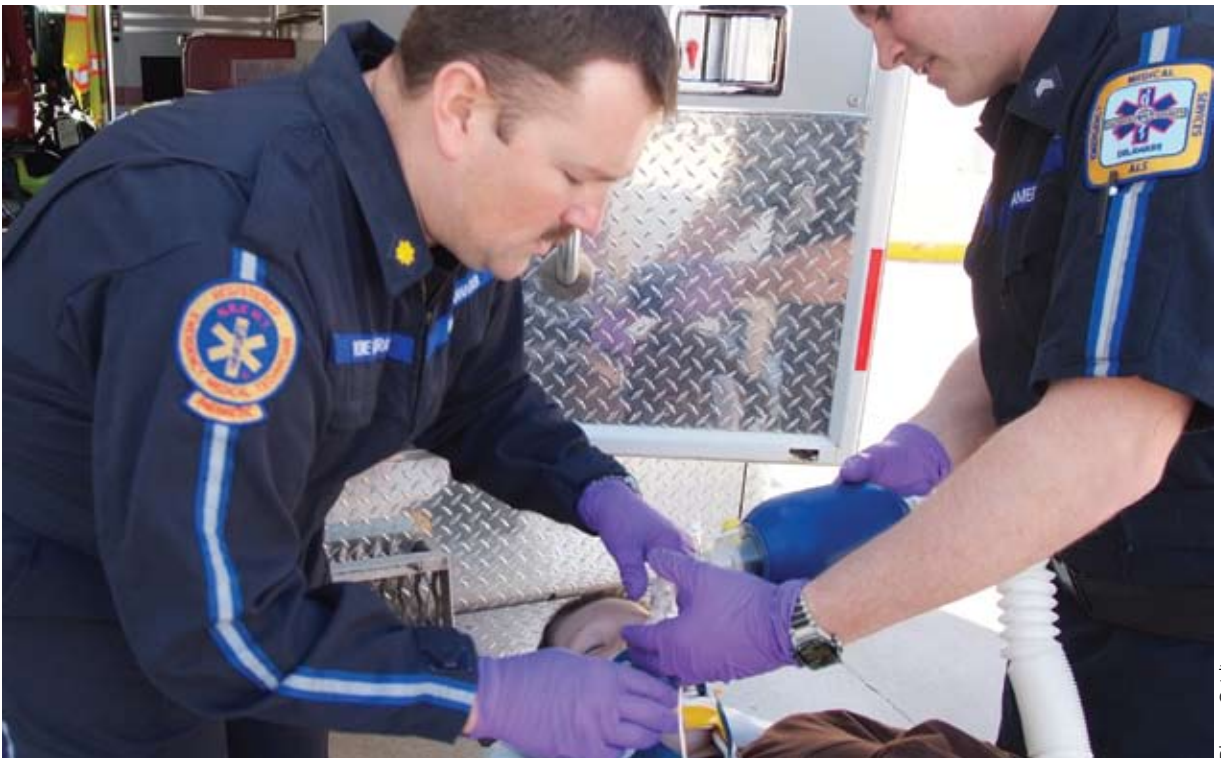

Photo: Oridion



By Pat Brandt, RN

Most prehospital providers don't consider the delivery of EMS a business. They feel they're in the "business" of saving lives, not money. But in these current economic conditions, EMS managers are being forced to evaluate cost-saving measures for their agencies. One common dilemma is how to maximize care at minimum cost. Another is making necessary budget cuts without reducing patient services. The solution: Use a cost-benefit analysis.

A cost-benefit analysis can help you determine which alternative is likely to provide the greatest return for a proposed investment. The goal of any system is to determine how well, or how poorly, a planned action will turn out. Cost-benefit analysis relies on the addition of positive factors and the subtraction of negative ones to determine

a net result. It's also frequently referred to as "running the numbers."¹

This type of analysis was originally used by managers to make monetary decisions regarding large-scale business projects. It can be effective, however, as an informal approach to making many economic decisions. In the early 1960s, it was extended to the assessment of the relative benefits and costs of health-care equipment and services.

The key to using cost-benefit analysis in EMS is to evaluate each service provided. You must take into account all potential costs and associated benefits the patient receives. The following is a basic example of how cost-benefit analysis can be used effectively in EMS as a management, budgetary and quality-improvement tool.

▲
Use of capnography to check ET tube placement may save your agency from an unnecessary and expensive lawsuit.

Capnography: A Cost-Benefit Analysis

The evaluation of the benefits vs. the costs of using capnography can be categorized into two primary areas:

1. Benefit vs. cost of providing appropriate treatment; and
2. The avoidance of medical malpractice lawsuits/settlements.

Three cases are presented here to illustrate the effect of proper capnography use and a potential cost-benefit analysis of how capnography could affect other EMS treatment modalities and supplies that could be involved in the care of patients managed by EMS crews. Except where indicated, all costs are for a single treatment.

Special Considerations:

1. It's impossible to definitively state how every patient will respond to care for the conditions presented and what additional care would actually be required. Therefore, the cases presented make patient response-to-care assumptions to simply illustrate possible treatments and expendable item expenses to demonstrate the potential cost-benefit analysis of capnography use.
2. For simplicity, the costs presented in this article for capnography use (\$10 per usage) are the disposable costs that would be incurred by a service in addition to the cost of adding capnography (estimated at \$3,000) to each cardiac monitor. If you wanted to, you could also factor in the hardware cost, amortized over time and by annual usage and factored into your cost-benefit analysis.

Example: If you amortized the \$3,000 per unit capnography add-on cost over five years (\$3,000/5 years = \$600/year), and by 700 uses per year (less than two uses per day by each), you could factor in a per-usage equipment amortization cost of \$0.86 per use (\$600/700 uses = \$0.86/use).

Patient 1 A COPD patient with confirmed wheezing

- Treatment: Administer albuterol and Atrovent via updraft.
- Cost: \$3.25–5, (see Table 1).
- Results: Capnography assessment shows a reversal of the initial shark-fin waveform and normalization of end-tidal carbon dioxide (EtCO₂).
- If the patient's condition is improved, minimal additional care would be required. However, if the patient is still in distress despite normalized EtCO₂, further assessment and treatment would be initiated.
- Discussion: Without capnography, EMS

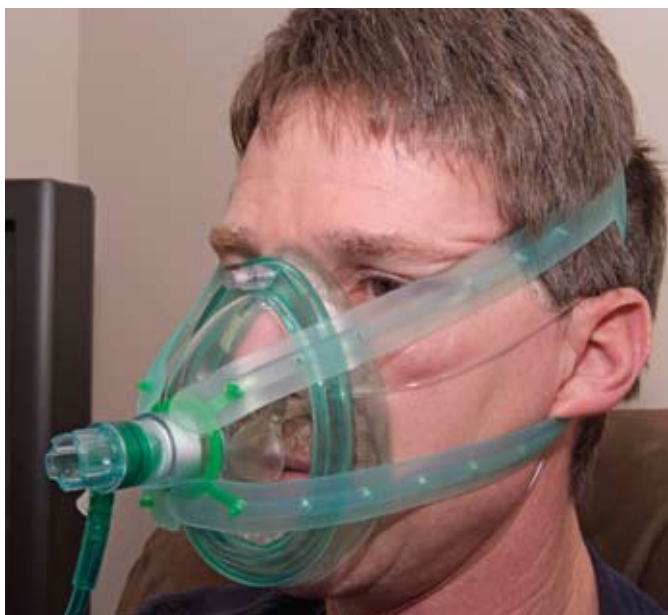

Photo: Oricidon

protocols could require further treatment that might be unnecessary. Continuing care with the use of Solu-Medrol and continuous positive airway pressure (CPAP)—a typical protocol—would add \$41–107 to this patient's treatment cost. The use of capnography (\$10 disposable cost), therefore, provides a potential cost savings of \$31–97.

▲ **Monitor the capnography level of patients receiving CPAP treatment through use of a dual nasal/oral cannula.**

Patient 2 A heroin overdose patient with a respiratory rate of 6

- Treatment: Assist the patient's ventilations with a bag-valve mask (BVM) and administer naloxone to reverse the actions of the heroin.
- Cost: \$27.50–50, (see Table 2, p. 12).
- Results: The capnography assessment reveals adequate ventilation with normalizing EtCO₂.

If the patient's airway is secure and no other clinical concerns are presented that dictate advanced airway use, you may not need to intubate this patient.

- Discussion: If the patient were intubated with an endotracheal (ET) tube or alternative airway, such as a laryngeal mask airway (LMA) or pharyngo tracheal lumen (PtL), an additional \$9–62.25 would be added to the patient's treatment cost. Therefore, the use of capnography could potentially present a cost savings of \$52.25.

▶ **TABLE 1: Treatment costs for asthma/COPD**

Capnography Disposables	\$10
Oxygen Administration	\$0.60–1.65
Nasal Cannula	\$0.60–0.80
Non-Rebreather O ₂ Mask	\$1.25–1.65
Updraft	\$3.25–5
Albuterol	\$0.50–1
Atrovent	\$0.75–1
Combivent	\$2
Nebulizer Kit	\$2–3
Magnesium Sulfate	\$1.50–6.60
Solu-Medrol	\$8–41
CPAP Mask/Circuit	\$33–66

Patient 3
Acute inferior wall myocardial infarction patient with a BP of 80/60

- Treatment: Initial IV fluid bolus of 300 mL.
- Cost: \$9.50–21, (see Table 3).
- Results: The capnography assessment after the first fluid challenge shows an improvement in the patient's EtCO₂ (from 22 to 28). After the administration of a second fluid challenge (no additional cost involved), the capnography assessment shows an improvement in EtCO₂ (from 28 to 35).
- Note: Capnography alone won't dictate whether further care or medications are necessary to stabilize this patient. If the patient's blood pressure and overall condition aren't improved after the fluid boluses, additional care may be necessary. However, for this simulated patient, we're assuming no additional care was necessary to illustrate what your cost savings would be.

- Discussion: Continuing with dopamine therapy would add \$18–28 to the cost of the patient's treatment. Therefore, the use of fluid challenges in conjunction with capnography provides a potential cost savings of \$8–18.

Having the assessment capability of capnography to determine that basic therapies are sufficient and additional therapy isn't needed can result in substantial cost savings for your service and the patient.

of medical procedures. Juries frequently award millions of dollars to patients, and legal fees are typically hundreds of dollars per hour, producing a significant unbudgeted expenditure to an agency. Therefore, capnography is one piece of clinical backup that can assist you in avoiding lawsuits.

How does capnography help in this area?

One of the most frequent EMS lawsuits involves undetected esophageal intubations. If the ET tube is improperly inserted into the esophagus and this error isn't recognized and corrected expediently, the result is a devastating hypoxia that causes severe brain injury and, ultimately, death. Continuous monitoring of capnography is the standard of care for detecting esophageal intubations, as well as for detecting subsequent dislodgement of ET tubes.³

Settlements for injury and wrongful death resulting from undetected misplaced ET tubes are often in the multimillion-dollar range.

Here are some recent case examples:

- In Ohio, a medical malpractice suit was filed against an EMS agency after the death of a 2-year-old boy. The patient died following a hospital transfer during which his ET tube became dislodged but wasn't detected. The final settlement wasn't made public.
- In Texas, a 41-year-old female suffered severe brain damage and died following an undetected esophageal intubation. Capnography wasn't in use. The case settled out of court for \$500,000.
- A Florida-based air ambulance service was sued when a 58-year-old female suffered severe brain damage and died when an ET tube became dislodged and was undetected. Capnography wasn't in use. The case was settled out of court for an undisclosed sum.

Another common cause of EMS lawsuits is injuries or deaths resulting from emergency vehicle crashes. In 1997, more than 15,000 accidents related to emergency calls occurred with emergency vehicles in the U.S. resulting in 8,000 injuries, 500 fatalities and millions of dollars in liability claims and vehicle repairs.⁴ One area in which these types of emergency transport crashes can be reduced is by not transporting nonviable cardiac arrest patients.

Civil rules, administrative concerns, medical insurance requirements and even reimbursement enhancement have frequently led to requirements that indicate the transport of all cardiac arrest patients to a hospital or emergency department. If these requirements are nonselective, they're inappropriate, futile and ethically unacceptable. Cessation of efforts in the out-of-hospital setting,

TABLE 2: Drug overdose/pain control and sedation reversal

(when assisted ventilations are required)

Capnography Disposables Cost	\$10
BVM	\$12–18
Reversal (with antidote):	\$6–68
Naloxone	\$6–23
Romazicon	\$58–68
IV Lock	\$1
IV Infusion Set	\$4–9
IV Fluid	\$3–4
IV Start Kit	\$2.50–8
Intubation:	\$6–72
ET Tube	\$2–6
LMA	\$21–42
Combitube	\$60–72
PtL	\$50–60
Tube Holder	\$4–10

TABLE 3: Shock (all types)

Capnography Disposables Cost	\$10
Fluid Therapy:	\$9.50–21
IV Infusion Set	\$4.00–9
IV Fluid	\$3–4
IV Start Kit	\$2.50–8
Vasopressor Therapy:	\$27.50–49
IV Infusion Set	\$4–9
IV Fluid	\$3–4
IV Start Kit	\$2.50–8
Dopamine	\$18–28

Medical Malpractice Costs

In 2006, at least 30 EMS lawsuits reached the Court of Appeals. A significantly higher number, probably in the hundreds, were decided at trial, and even more were settled out of court.²

The most common causes for EMS lawsuits are negligent vehicle operation and improper performance

following system-specific criteria and under direct medical control, should be standard practice in all EMS systems.⁵

One component of cardiac arrest termination protocols is a sustained EtCO₂ of less than 10 mmHg, often secondary to asystole present after two rounds of cardiac arrest drugs.⁵ The continuous monitoring of capnography can confirm a EtCO₂ reading of less than 10 mmHg, along with your protocols and other clinical assessment parameters, and assist you in terminating resuscitative efforts and prevent unnecessary, and often dangerous, emergency transport.

Another potential lawsuit involves the patient who's been sedated or physically restrained. Restraint lawsuits are generally related to brain injury or death from "positional asphyxia," and in the sedated patient, from hypoventilation hypoxia.

The use of continuous capnography to monitor these patients can assist your crews in reducing the chance of missed episodes of apnea or respiratory distress due to patient positioning of restraints. EMS providers alerted to the fact that a patient is hypoventilating could enable them to adjust restraints, reposition the patient or reduce or stop sedation long before significant hypoxia occurs.

Other EMS lawsuits involve the delivery of inappropriate treatment or the failure to provide appropriate treatment. Capnography cost-effectively provides assessment information that guides treatment in a variety of common EMS emergencies, including respiratory emergencies, metabolic emergencies and shock.

Conclusion

Providing quality patient assessment and care are our primary goals. Reducing service costs, maximizing the use of limited financial resources and avoiding lawsuits are secondary—but important—goals. Capnography is a powerful clinical tool that, when used appropriately and in conjunction with a thorough, systematic patient assessment can assist your service in achieving each goal, improving patient care and enabling your service to operate in an efficient and cost-effective manner. •

Pat Brandt, RN, has worked in EMS for more than 25 years as an EMS transport nurse, an emergency department nurse, a paramedic educator and an EMS quality manager. She recently retired as the EMS quality manager and paramedic instructor for Orange County (Fla.) Fire Rescue Department. She also served on the state committee in Florida that developed and supported the legislative rules requiring the

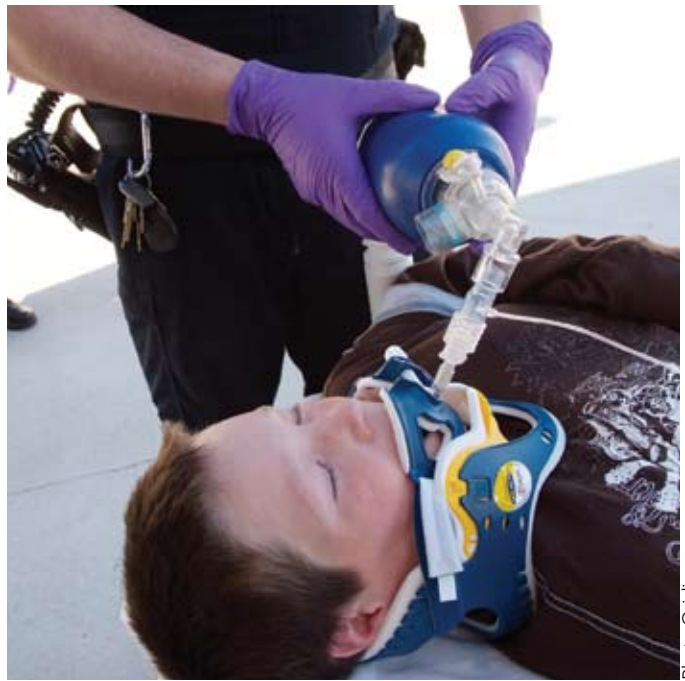


Photo: Oridion

use of continuous waveform capnography by Florida EMS agencies. Contact her at brandtp@bledsoe.net.

Improper ET tube placement can be immediately detected with capnography use.

Disclosure: The author has completed contract work for Medtronic/Physio Control Corporation, a manufacturer that utilized Oridion capnography technology in their cardiac monitors.

References

1. Reh JF: *Cost Benefit Analysis*. <http://management.about.com/cs/money/a/CostBenefit.htm>
2. Weaver J. *Surviving a Lawsuit*. EMSWorld. www.emsworld.com/publication/article.jsp?pubId=1&id=6186
3. Silvestri S, Ralls GA, Krauss B, et al. The effectiveness of out-of-hospital use of continuous end-tidal carbon dioxide monitoring on the rate of unrecognized misplaced intubation within a regional emergency medical services system. *Ann Emerg Med*. 2005;45:497–503.
4. *National Aeronautics and Space Administration. NASA to Test Emergency Traffic Vehicle in Monrovia*. <http://hypography.com/news/environment/29132.html>
5. American Heart Association. Part 8: Adult Advanced Cardiovascular Life Support. *Circulation*. 2010;122:S729–767.

To download a PDF of this supplement, go to

www.jems.com/special/capnography



A FORM OF TRIAGE

Capnography use for the conscious & non-intubated patient

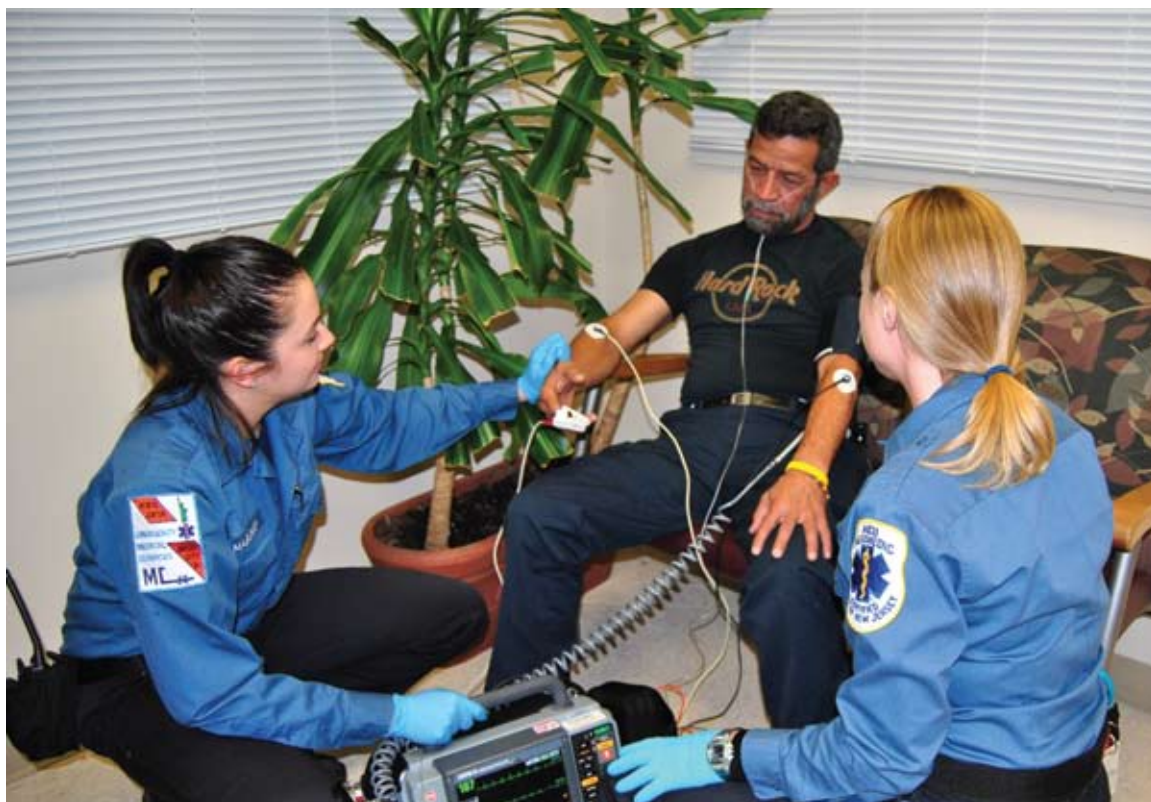

Photo: Jim Woods



**By Bob Page, AAS,
NREMT-P, CCEMT-P,
NCEE**

It's fall—also known as respiratory season—and you're responding to an emergency call for a 50-year-old male patient who has severe shortness of breath. On scene, you're met by an excited woman who's yelling, "Hurry! He's really bad this time." You get a déjà vu feeling.

You're led to a man who's sitting on the couch in a tripod position in obvious distress. His lips look dusky and slightly blue. He has on a nasal cannula, but the oxygen (O₂) bottle is empty. On the end table are two inhalers: albuterol and DuoNeb.

After some questions, your EMT partner grabs the monitor and applies supplemental oxygen at 5 liters per minute (LPM) via a nasal cannula that also measures capnography. Pulse oximetry is applied, and the patient is prepped for a 12-lead ECG. The initial printout includes three parameters: heart rate, pulse oximetry and capnography, (see Figure 3, p. 16). The patient is in sinus tachycardia at 120, his pulse oximetry reads 75%, and the capnogram shows obstructed hypercapnia and an end-tidal carbon dioxide (EtCO₂) reading of 100 mmHg.

Recognizing the severity of the situation, you quickly locate a nebulizer mask assembly, place albuterol and ipratropium in it and apply it to the patient. As you auscultate the lungs, you hear coarse crackles in the upper lobes and expiratory wheezing lateral vesicular. After four minutes, the patient is able to speak in full sentences, his pulse oximetry has increased to 94%, and the capnogram

Figure 1 | Before Treatment

This waveform indicates uneven alveolar emptying caused by a bronchospasm. Note the delay on the upstroke waveform that some call a shark fin. The EtCO_2 value can be used to triage the severity of an asthma attack. Early asthma attack will tend to hyperventilate, so a low CO_2 (hypocapnia) is normal, as the patient tires the EtCO_2 rises to and past normal.

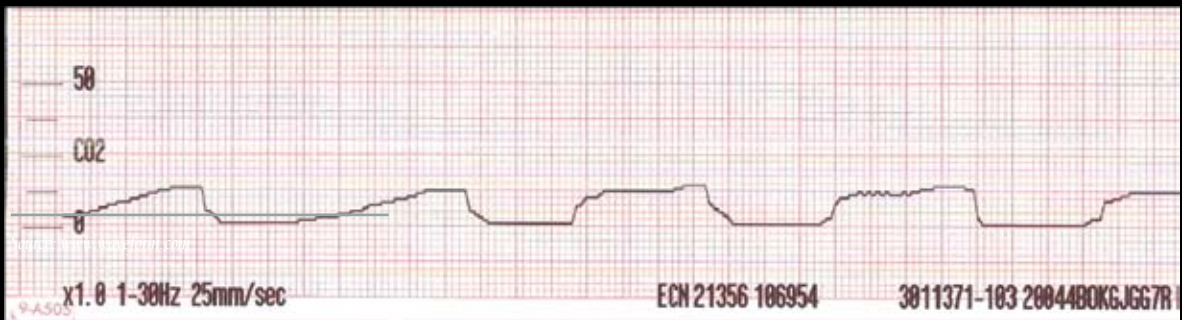
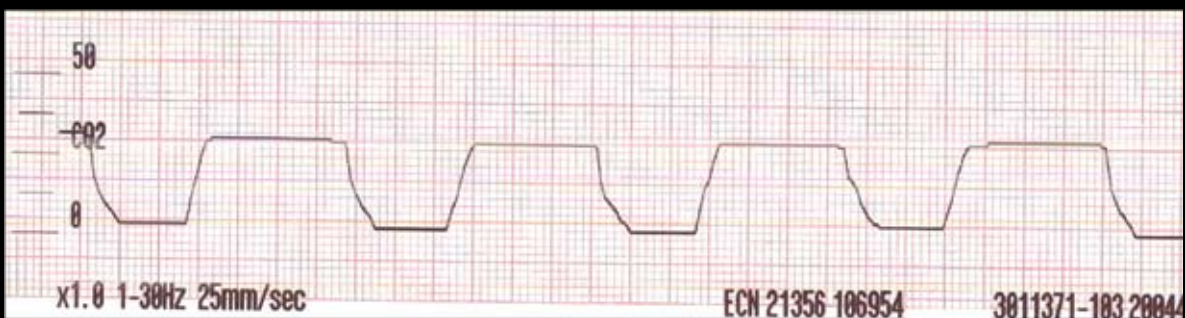
Figure 2 | After Treatment

This is the same patient after a nebulized albuterol treatment. This shows objective proof that this patient had a bronchospasm that was relieved by a beta-2 agonist. This objective proof of improvement can only be documented through capnography. Note that the time it takes to empty the alveoli is obviously shorter. We can also monitor the patient continuously and see if the spasms return.



shows normal waveform with an EtCO_2 of 48. His heart rate has slowed a bit to 100. Your transport time of 10 minutes is uneventful, and the patient is turned over to emergency department staff.

Discussion

Respiratory emergencies are a common complaint that EMS providers face daily. Over the years, we've been taught to assess patients based on subjective criteria, including respiratory rate, observed work of breathing, accessory muscle use, auscultation for breath sounds, skin signs and mentation. With technology, we've added heart-rate monitors and pulse oximetry. Even with all of these assessment tools available, the lack of a comprehensive objective tool has left much to be desired, completing a differential diagnosis has been difficult.¹²

Capnography represents an important clinical upgrade. It can be used as a triage tool for the severity of respiratory emergencies and be a factor in deter-

mining initial therapy.³ It can also be used as a tool to track the effectiveness of therapy. It doesn't replace traditional assessment techniques. Rather, it enhances the clinical assessment. It's an objective measurement of fundamental life functions: airway patency, breathing adequacy and circulatory efficiency.

A Life Process

Breathing is a chemical thing. The essential stimulus to breathe in the healthy adult comes from CO_2 levels in the brain and pH of their cerebral spinal fluid (CSF). When these levels increase, chemoreceptors report it to the medulla, and this triggers respiratory effort.

The inhalation of O_2 assists in CO_2 elimination. O_2 transported to the cells is used for metabolism. As a byproduct of metabolism, CO_2 is offloaded from the cells into the blood and carried as bicarbonate to the lungs, where it's eliminated. We can then measure what comes back. This is the "circle of life," so to speak. So capnography helps you measure the funda-

If someone loses their stimulus to live, they have clinical depression. If they lose their stimulus to breathe, they have respiratory depression.

mental life process.

If someone loses their stimulus to live, they have clinical depression. If they lose their stimulus to breathe, they have respiratory depression. If they have respiratory depression, they don't have the "desire" to eliminate EtCO₂, and their levels go way up. This is one way we can use capnography as a triage tool in patients who may be under the influence of "something." This illustrates how capnography can also be used to assess the adequacy of the patient's breathing or your assisted breathing.

Measurement

Early capnometry, as we know it in EMS, was qualitative: We used to just watch a litmus paper change from purple to yellow. This was only possible on the intubated patient. However, technological advances have now made it possible to monitor non-intubated patients.

Early sidestream technology, and now Microstream® technology, have made it possible to assess all age groups, intubated or not. This is accomplished by a nasal or nasal/oral cannula that captures exhaled CO₂ from the nose, mouth or switch breathers. EMS providers can even deliver oxygen via this cannula at the same time they're reading the EtCO₂. This special cannula can also be used with a non-re-breather mask and with a continuous positive airway pressure (CPAP) device.

Understanding CO₂ Values

The normal value of CO₂ in your body is 35–45 mmHg. In cases of normal perfusion, EtCO₂ (what you exhale) should be within 5 mmHg of the CO₂ blood levels. The mean difference is 2 mmHg. EtCO₂ that is greater than 45 mmHg is known as *hypercapnia*, and EtCO₂ that's less than 35 mmHg is called *hypocapnia*.

Figure 3 | Triage

The patient has a SpO₂ of 75% (hypoxemia) and an EtCO₂ reading of 98 (hypercapnia) with a bronchospasm. This indicates respiratory failure secondary to a bronchospasm. The tachycardia is obviously compensatory. The condition must be managed aggressively with immediate bronchodilator therapy.

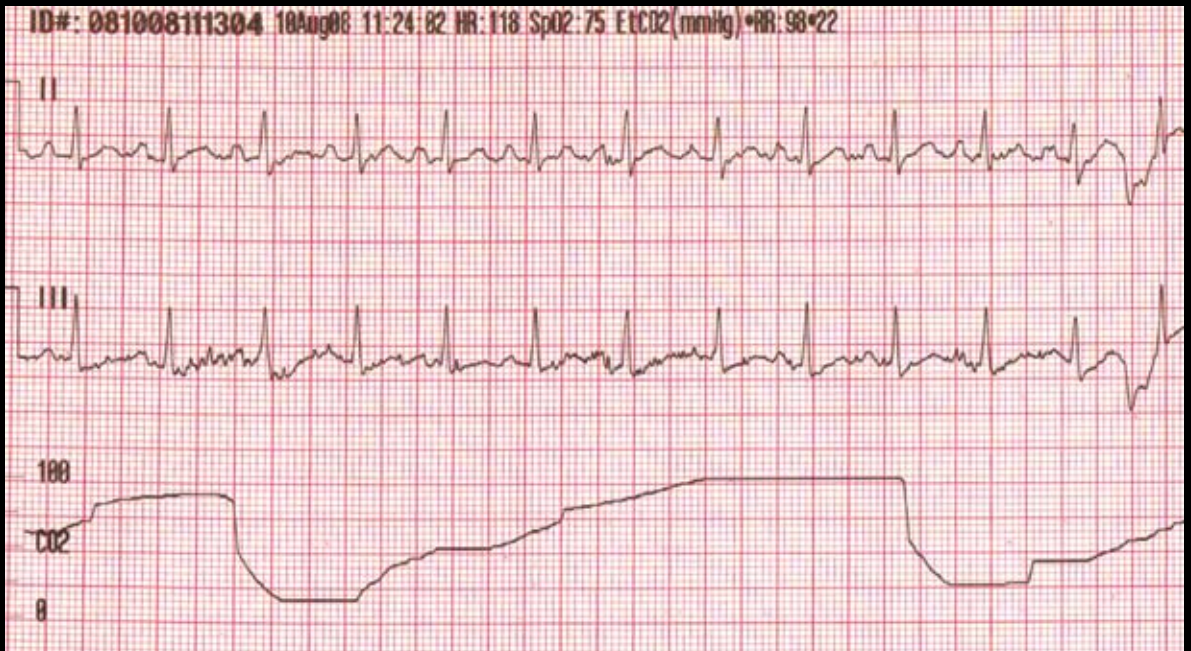


Figure Bob Page

Clinically speaking, if a patient has hypocapnia, there's usually one of three conditions contributing to it: hyperventilation, hypoperfusion or hypothermia.

Hyperventilation occurs when a patient blows off more CO₂ than they're making.

The underlying condition could be hypoperfusion. Remember, if CO₂ doesn't get back to the lungs, it can't be blown off (or detected) by EtCO₂ monitoring. So consider shock, pulmonary embolism, hypotension and pulselessness. Always take capnography readings in the context of the rest of the exam.

Hypocapnia could also be caused by hypothermia because of decreased metabolism, which produces lower amounts of CO₂.

All acute patients with hypercapnia are considered to be "sick." This can indicate hypoventilation (i.e., patients make more CO₂ than they blow off). High levels of exhaled EtCO₂ mean high levels of CO₂ in the blood. This leads to acidosis.

You're probably thinking, "What if they're a CO₂ retainer?" Good question. A CO₂ level of 50–60 could be normal for them because their medulla is accustomed to high levels over a long period of time. How can you tell? Well, if they're indeed a hypoxic breather, giving them oxygen could depress their stimulus, causing the CO₂ to go up.

A partial pressure CO₂ (PaCO₂) level that's above 50 represents ventilatory failure. The patient discussed at the beginning had an EtCO₂ of 100. This is critically dangerous. Add an SpO₂ reading of 75%, and you have respiratory failure, which requires bold, aggressive management.

The Waveform

An EtCO₂ value without a waveform is like a heart rate without an ECG. Capnography measures CO₂ levels and draws a picture of the CO₂ flow over time. CO₂ comes from the alveoli. So if the capnogram is a square, obstruction to the flow of CO₂ isn't occurring. On the other hand, bronchospasm produces uneven alveolar emptying and, thus, an uneven capnogram.

This means some alveoli rapidly purge their CO₂ and others may be more constricted, so it takes longer to empty their CO₂. This is what produces the severe angle to the upstroke and plateau on the waveform. (see Figure 1, p. 15).

Bronchospasms respond well to bronchodilator therapies, such as albuterol and or ipratropium. In our case, the patient had a bronchospasm with respiratory failure. The rapid triage with capnography gave the paramedic objective evidence of what the problem was, its severity and how to treat it. Further, patient observations and the capnogram demonstrated objective proof that the patient did have a broncho-

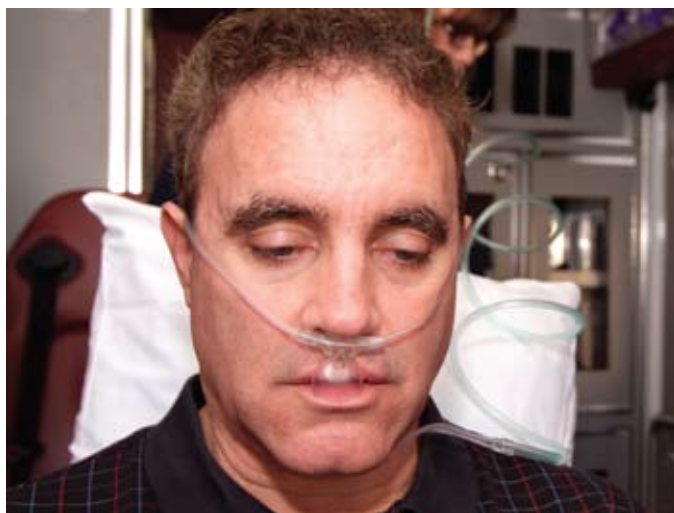

Photo: Oridion

spasm, and it was relieved by albuterol/ipratropium, (see Figure 2, p. 15).

▲ EMS providers can deliver oxygen via a nasal/oral cannula while monitoring EtCO₂.

Conclusion

This case is an outstanding, real example of the amazing benefit of capnography for patient triage, determination of severity, therapy and post-therapy monitoring. *Special note:* Some of the more traditional assessments were deferred because of this patient's severe condition. For example, the crew started therapy before listening to breath sounds. Remember, capnography is a clinical upgrade. The objective findings of respiratory failure because of bronchospasm needed immediate bronchodilator therapy. ●

Bob Page, AAS, NREMT-P, CCEMT-P, NCEE, is a nationally recognized expert in capnography and has presented seminars nationally and internationally for more than 12 years. His capnography courses "Riding the Waves" and "Slap the Cap" are among the first comprehensive, nationally presented capnography courses. Contact him at www.multileadmedics.com or lead2noclue@mac.com.

Disclosure: The author has reported no conflicts of interest with the sponsors of the supplement.

References

1. Ackerman R, Waldron RL. Difficulty breathing: Agreement of paramedic and emergency physician diagnoses. *Prehosp Emerg Care*. 2006;10:77–80.
2. Lett D, Petrie DA, Ackroyd-Stolarz S. Accuracy of prehospital assessment of acute pulmonary edema. Abstract. *CJEM*. 2000;3:1423.
3. Corbo J, Bijur P, Lahn M, et al. Concordance between capnography and arterial blood gas measurements of carbon dioxide in acute asthma. *Ann Emerg Med*. 2005;46:323–327.

GOTCHA!

Challenging waveforms that could fool an expert

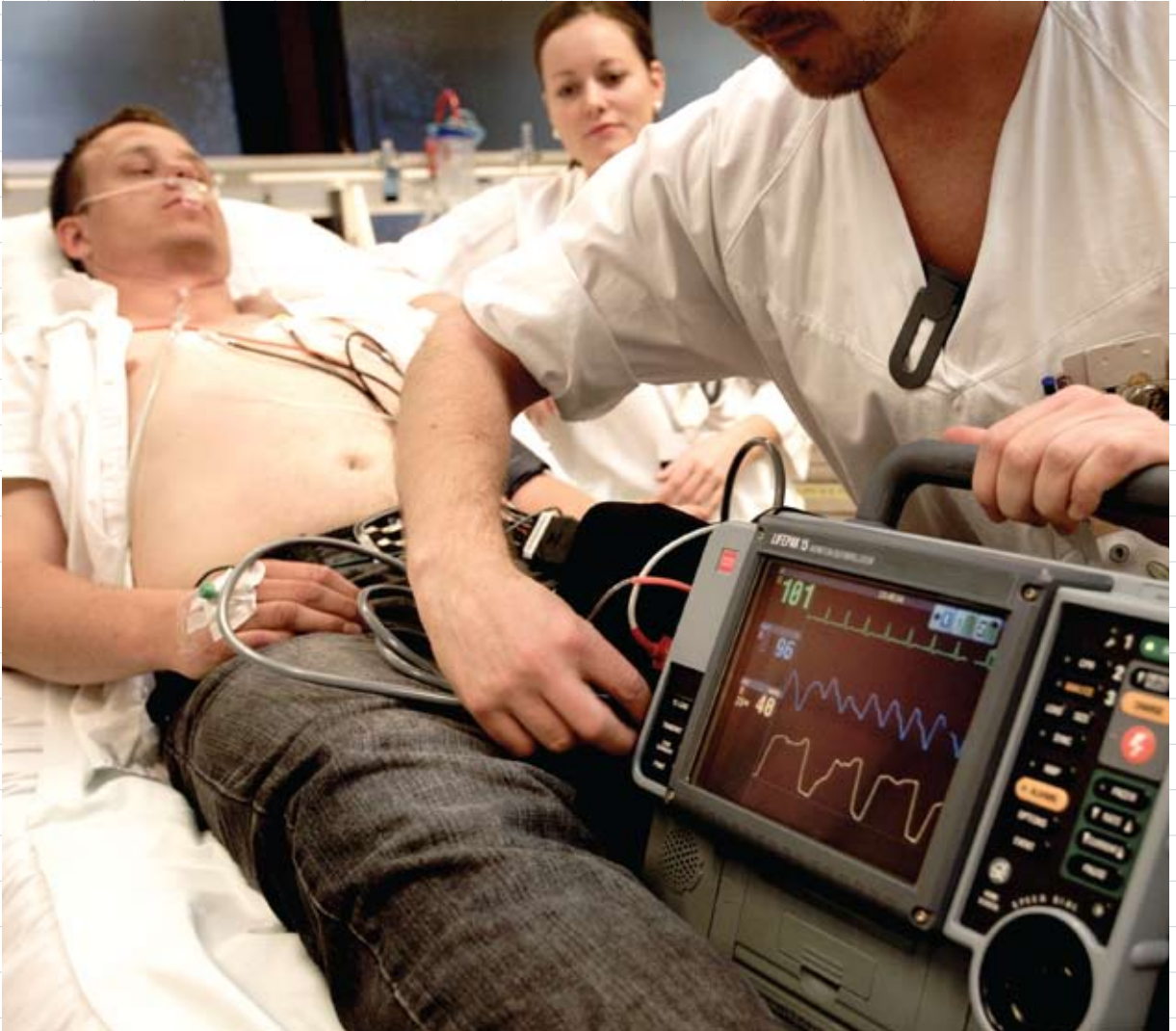

Photo Pat Brandt



By Pat Brandt, RN

As a relatively new nurse working in the emergency department, I remember a cardiologist who would come by before making his hospital rounds. He'd throw an ECG strip down on the desk, give us a quick scenario and ask, "What is it?" It was always an interpretation that would look obvious but involve more than met the eye. So when we'd give him a quick, but incorrect, answer, he'd respond with, "Gotcha!" He'd then explain the correct answer and be on his way. So I wanted to present a few cases to

you and share some of the lessons I once learned. A snap judgment in medicine could prove disastrous for your patient.

Discussion

These cases certainly don't show the typical capnography waveforms. However, just like with ECG tracings, understanding the relationship between each component of the capnography waveform and each phase of the ventilatory cycle will help you understand what's going on in these case studies.

Case 1

The patient is a 70-year-old male in cardiac arrest. He's intubated, and CPR is in progress. It looks like the person ventilating with the bag-valve mask (BVM) had way too much coffee today. What do you think?

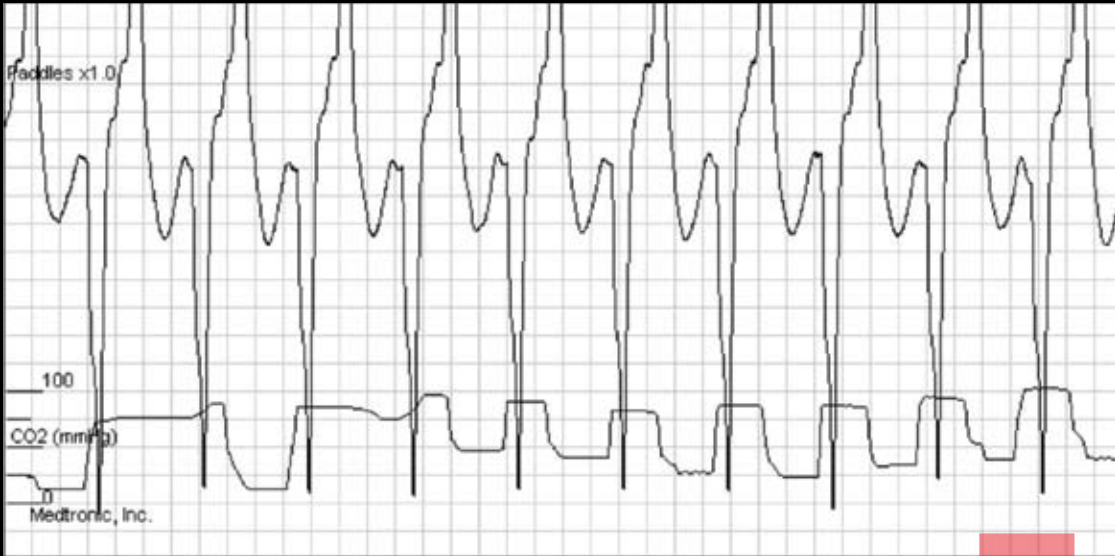
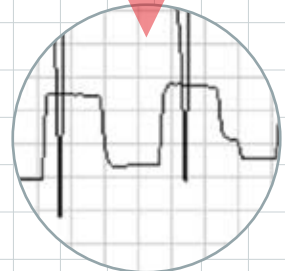



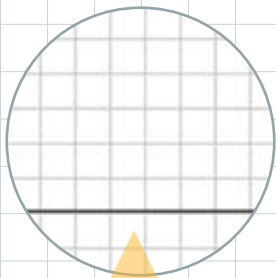
Figure Pat Brandt

The first clue when inspecting the capnography waveform is that the ventilatory rate is way too fast. This finding isn't surprising because studies have shown that ventilation rates in cardiac arrest are frequently faster than recommended.

However, this rate is in the 80–100 range and, it would be difficult—if not impossible—to accomplish this with a BVM. On further investigation, you find that chest compressions are being provided by a mechanical CPR device, and the capnography waveforms are primarily related to the air that's moving in and out of the chest with each compression.

It's also interesting to note that the end-tidal carbon dioxide (EtCO_2) is quite high, which is also often seen with the improved compressions provided by a mechanical CPR device. In fact, the EtCO_2 is so high that the scale has changed from 0–50 to 0–100. It's always important to make note of the scale so that patient assessments are accurate. It would be interesting to see if application of a transthoracic impedance device, such as a ResQPOD, would prevent air movement into the chest between compressions and improve the patient's status.





Case 2

The patient is an 88-year-old female in cardiac arrest. CPR is in progress and she is intubated. Was the endotracheal (ET) tube correctly placed?

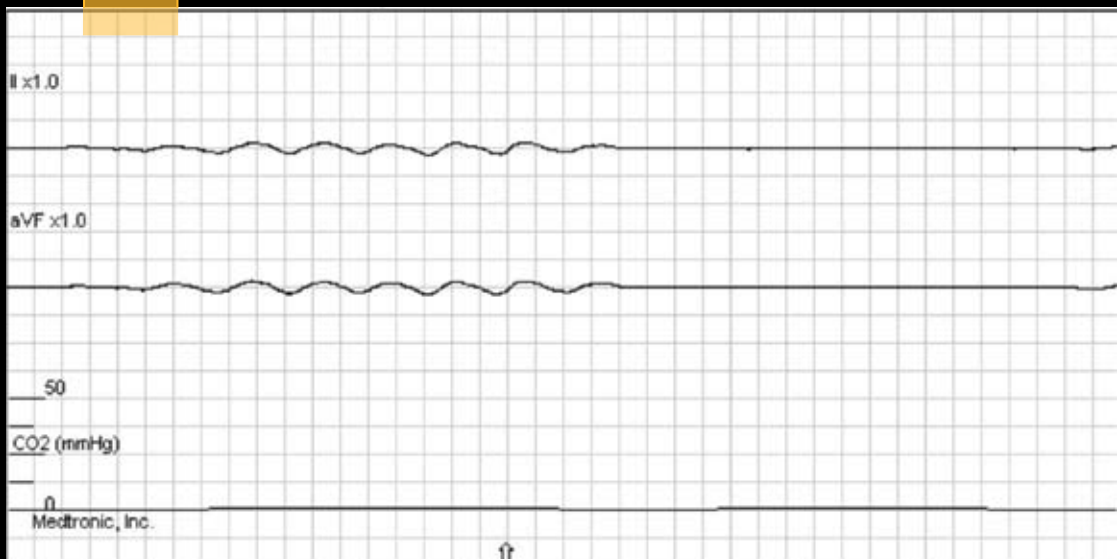


Figure Pat Brandt

A quick glance at the screen might suggest that this patient has been esophageally intubated. However, if you look closely, you'll note two very small waveforms that confirm ET tube placement. What this waveform is actually showing is an extremely low cardiac output that may be associated with inadequate chest compressions or a non-viable patient. EtCO₂ readings don't register when perfusion

is this low, so it's a good idea to print a quick strip before the decision is made to extubate. You should also evaluate whether improved compressions increase the height of the capnography waveform. If there's no improvement, research has shown that an EtCO₂ that remains less than 10 mmHg after 20 minutes of advanced cardiac life support therapy indicates a non-viable patient.¹

Case 3

The patient is a 65-year-old female with a two-day history of malaise and a gradual decrease in her level of consciousness. What's causing that unusual capnography waveform?

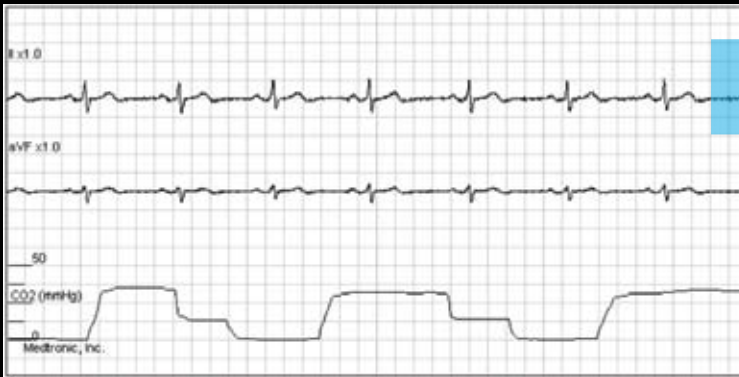

Figure Pat Brandt

This patient's unusual waveform is the result of severe kyphoscoliosis, which has compressed the right lung, resulting in differential lung emptying and a biphasic waveform. The respiratory rate and EtCO₂ are in the normal range, so there's confirmation at this point that the patient's ventilation, perfusion and metabolic activity are adequate.

Case 4

The patient is an 18-year old-male who was involved in a motor vehicle crash. He has a closed head injury and has been intubated. What does this unusual waveform reflect?

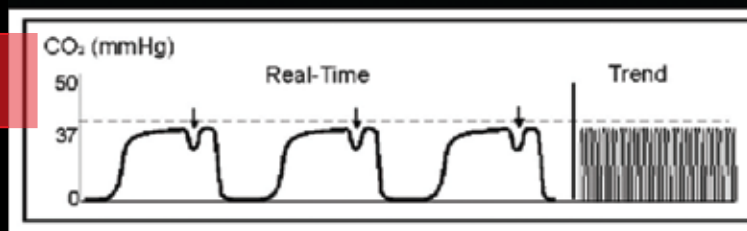
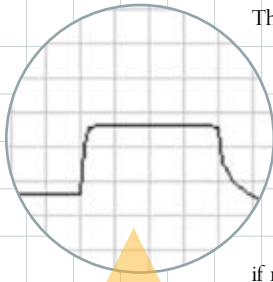


Figure Pat Brandt

This waveform has an anomaly known as a "curare cleft." In this case, intubation was accomplished with the use of rapid-sequence intubation after the administration of muscle relaxants. As the effects of the muscle relaxants subside, spontaneous ventilatory efforts are reflected as a "cleft" in the capnography waveform. The depth of the cleft is inversely proportional to the degree of drug activity. The position of the cleft is usually fairly constant on each waveform but isn't necessarily present on every breath. This is a good indication that additional medication should be administered.

A Final Word



The case studies presented here are just a few of the many variations in capnography waveforms that may challenge your practice. Understanding the physiology of capnography and using this valuable assessment tool when indicated will help you to identify early warning signs of ventilatory or perfusion insufficiency, identify metabolic abnormalities, determine if medications are needed, improve cardiac arrest management, confirm appropriate ET tube placement, distinguish pulmonary from cardiac pathophysiology and generally provide better care to critical patients. •

Pat Brandt, RN, has worked in EMS for more than 25 years as an EMS transport nurse, an emergency department nurse, a paramedic educator and an EMS quality manager. She recently retired as the EMS quality manager and paramedic instructor for Orange County (Fla.) Fire Rescue Department. She also served on the state committee in Florida that developed and supported the legislative rules requiring the use of continuous waveform capnography by Florida EMS agencies. Contact her at brandtp@bledsoe.net.

Disclosure: The author has completed contract work for

Case 5

The patient is a 4-year-old female with a history of frequent upper-respiratory infections. She's now having difficulty breathing and is being transported with oxygen administered by mask. What's significant about her capnography waveform?

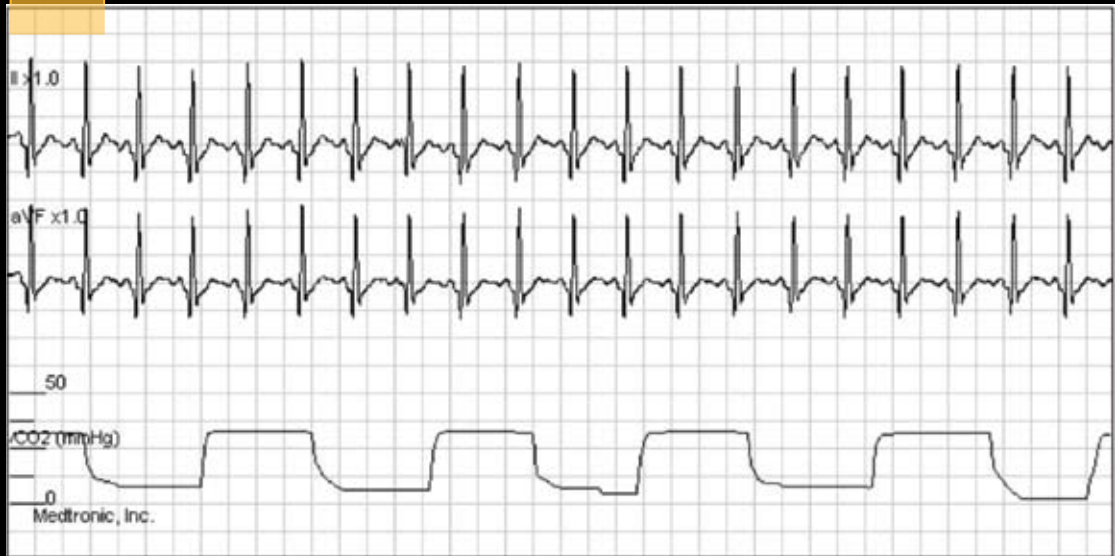


Figure 1 Pat Brandt

This capnogram seems to be normal for a pediatric patient, except that the respiratory rate is increased, even for a 4-year-old. The EtCO₂ is also lower than normal, which would be expected with the increased respiratory rate. There's no evidence of bronchospasm, yet the baseline never returns to zero. This finding is significant because it indicates re-breathing of CO₂ that's never totally cleared or "washed out" on inhalation.

In this case, it's probably caused by the rapid respiratory

rate and possibly by the oxygen mask, especially if the flow rate has been set too low for the device. Other causes of re-breathing include air trapping, found in patients with asthma or chronic obstructive pulmonary disorder, poor head and neck alignment, shallow breathing that doesn't clear the dead space or a ventilator circuit problem.

It's important to note that the amount of elevation from baseline will also show an artificially elevated EtCO₂ of the same amount.

Case 6

The patient is a 35-year-old-female who's in her third trimester of pregnancy. She has a history of type 1 diabetes mellitus and is unresponsive and very dehydrated upon your arrival with a blood glucose level of 350. What's the cause of this unusual waveform?

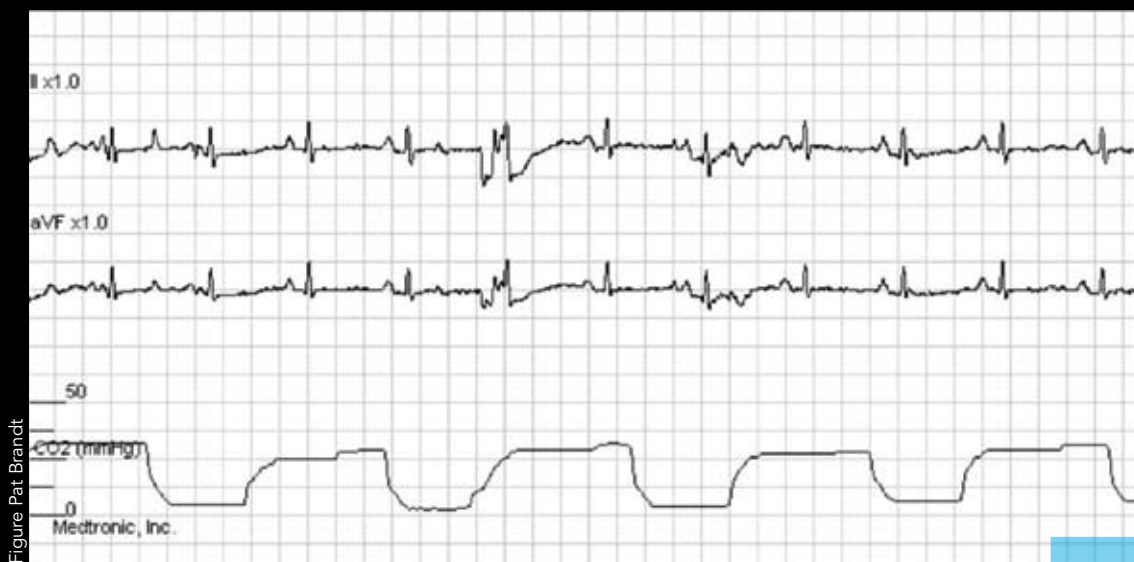

Figure Pat Brandt

The shape of this waveform represents a normal physiological variant seen in pregnancy and in obese patients because their diaphragm can't flatten on inspiration. There's a terminal upswing of the waveform at the end of Phase III, which can sometimes mimic the shark-fin appearance seen with bronchospasm. Pregnant patients often present with an artificially elevated EtCO₂ reading by waveform even though their partial pressure CO₂ levels are slightly lower to provide a gradient for carbon dioxide to flow from the fetus to the mother. In this waveform,

the EtCO₂ reading would be 35, but the actual EtCO₂ is 28. This is a good example of why it's so important to view the waveform in addition to the EtCO₂ reading. This case helps confirm that the patient's decreased level of consciousness is due to diabetic ketoacidosis (DKA). A Philadelphia study found that patients with elevated blood sugars and an EtCO₂ of less than 29 are in DKA 95% of the time.² The remarkable lowering of the EtCO₂ is attributable to Kussmaul ventilations, which attempt to blow off CO₂ (respiratory acid) to buffer the plummeting pH level.

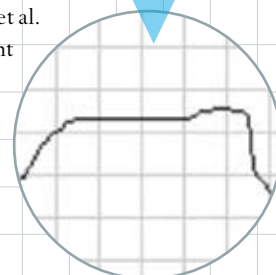
Medtronic/Physio Control Corporation, a manufacturer that utilized Oridion capnography technology in their cardiac monitors.

References

1. Levine RL, Wayne MA, Miller CC. End-tidal carbon dioxide and outcome of out-of-hospital cardiac arrest. *N Engl J Med.* 1997;337:301–306.
2. Fearon, DM, Steele DW. End-tidal carbon dioxide predicts the presence and severity of acidosis in children with diabetes. *Acad Emerg Med.* 2002;9:1373–1378.

Additional Resources

- Krauss B. Advances in the use of capnography for non-intubated patients. *Israeli. J Emerg Med.* 2008;8:3–15.
- Lightdale JR, Goldmann DA, Fedlman HA, et al. Microstream capnography improves patient monitoring during moderate sedation: A randomized, controlled trial. *Pediatrics.* 2006;117:1170–1178.





Capnography. Because you need to know if your patient is breathing.

7:45 a.m. Lights, sirens, a frantic family member. But in the midst of the chaos, you're calm. Because you know your patient is breathing. *Capnography* gives you clear and immediate ventilation assessment and provides the earliest, most accurate indication of respiratory distress. With only minutes or even seconds to make decisions that could mean life or death, you know this is no time to stop and count respiratory rate.

No other vital sign gives you a complete picture of your patient's ventilatory status so that you can assess, treat, and notify the emergency room what to expect.

With all the uncertainties each call brings, there is one certainty you can count on: capnography. Simple. Fast. Accurate. *Certainty in an uncertain world.*

Capnography has long been the standard for monitoring intubated patients. Learn why capnography is becoming the new standard for non-intubated ventilation monitoring at www.oridion.com/ems.



Oridion®